

A Step by Step Guide to a

CLASS

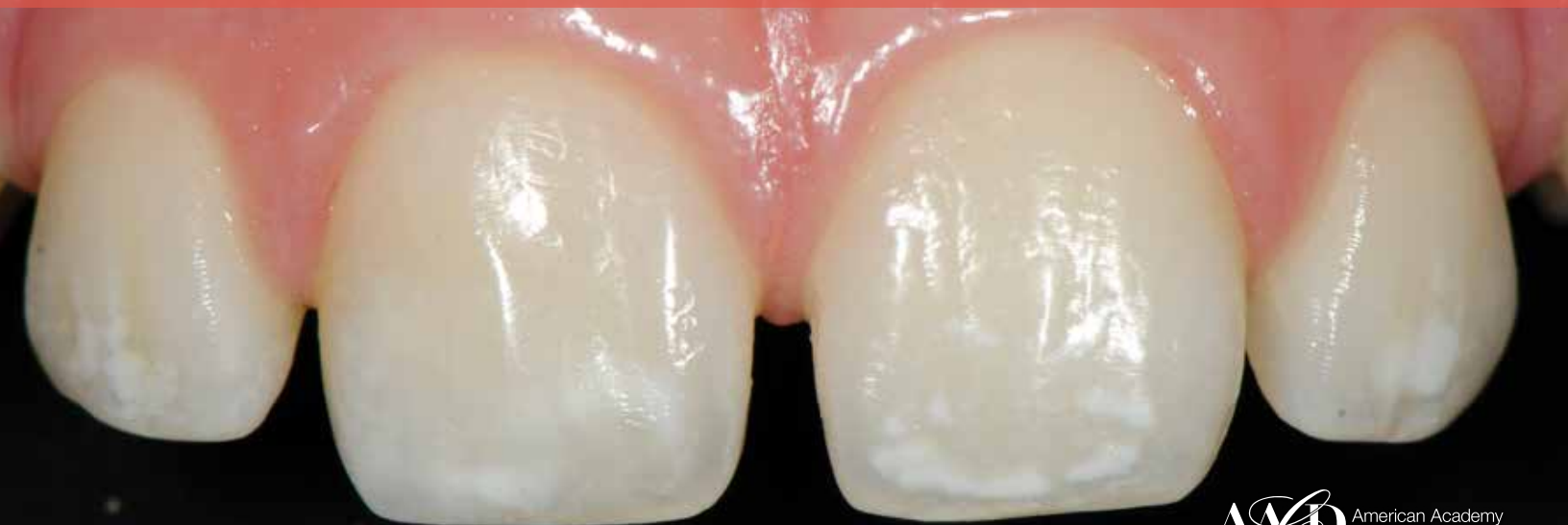Direct Resin Restoration of a Fractured Tooth

By Ingrida Ivance, DDS

with an introduction and commentary by

AACD Accreditation Examiner James H. Peyton, DDS, FAACD

Adapted from the articles “Undetectable Integration of Composite Resin with Natural Tooth Structure Accreditation Clinical Case Report, Case Type IV: Class IV Direct Resin Restoration” by Ingrida Ivance, DDS and ““Passing the ‘Litmus Test’: Class IV Direct Resin Restoration: Fracture Case” by James H. Peyton, DDS, FAACD which first appeared in the AACD’s *Journal of Cosmetic Dentistry*, Volume 29, Issue 1.



INTRODUCTION

The Class IV fracture repair is everyday dentistry that many patients need and should be able to afford. Many dentists do not take the time to learn a polychromatic layering process and finishing and polishing techniques that can yield natural, lifelike results. In a case like the one presented here, a well-done composite resin can look better, be less traumatic to the pulp, and be more conservative than “grinding down” the tooth for a full crown. And yes, the restoration can last a long time! The dentist can be a true artist and is in complete control of the situation. Read on for a step by step guide through a case that demonstrates clinical excellence and passes the AACD Accreditation criteria for a Class IV Direct Resin Restoration.

— James H. Peyton, DDS, FAACD

Figure 1 : Full-face smile before.



For young patients, Class IV direct resin restorations are an excellent treatment modality for restoring fractures of anterior teeth, especially central incisors. This case illustrates how direct composite resin can be used to provide an excellent and minimally invasive restoration that will clearly benefit the long-term biomechanical behavior of affected teeth.

THE CASE

The patient, a 10-year-old boy, came to the office with his mother to restore the fractured incisal two-thirds of his maxillary right central incisor (Fig 1). The etiology of the tooth fracture was a fall from a bicycle two days earlier. The fractured

fragment of the patient’s tooth had been lost. The patient’s mother sought high-level, conservative, restorative treatment to restore the fractured tooth to its natural appearance. The patient had an unremarkable medical history and a dental history that included routine fillings and sealants.



“The ideal patient for this type of treatment is like Dr. Ivance’s young patient in this case.”

— James H. Peyton, DDS, FAACD

THE PROCESS

1

EXAMINATION. A thorough examination was performed and appropriate radiographs taken. The clinical exam revealed no signs or symptoms of temporomandibular joint or occlusal disorder. Visual and tactile inspection of the soft tissue showed them to be within normal limits and free of pathology. The teeth were evaluated and checked for any possible fractures, pulp exposures, and mobility. There was no radiographic or clinical evidence of pulpal exposure or root fracture and the patient had experienced no spontaneous pain since the accident. Tooth #8 responded to cold, was negative to percussion, and did not exhibit mobility (Figs 2-5).

2

TREATMENT PLAN. A Class IV composite restoration was the treatment of choice because of the patient’s age, and to conserve remaining tooth structure. Class IV composite combining microhybrid and microfill that are completed with effect materials would fulfill the patient and his mother’s expectations and meet current biomechanical and esthetic standards.

3

PATIENT EDUCATION. The following esthetic and restorative issues were discussed with the patient’s mother: functional issues; longevity; possible need for endodontic management and discoloration of the residual tooth structure and root of the traumatized tooth; recare and maintenance: observation, management, and evaluation.

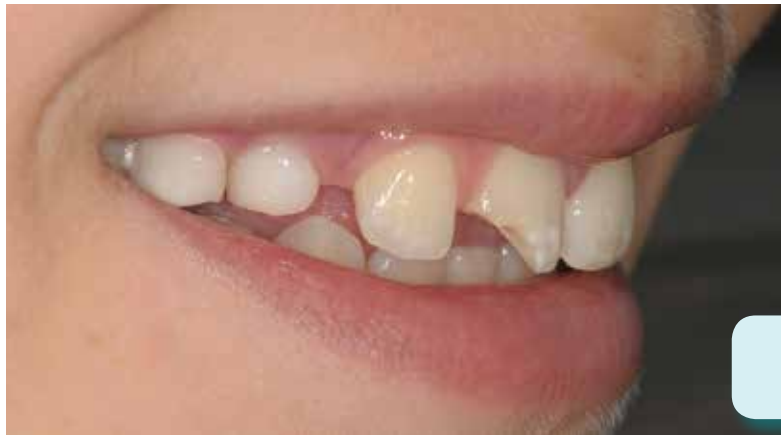

Figure 2: Preoperative close-up right lateral view.

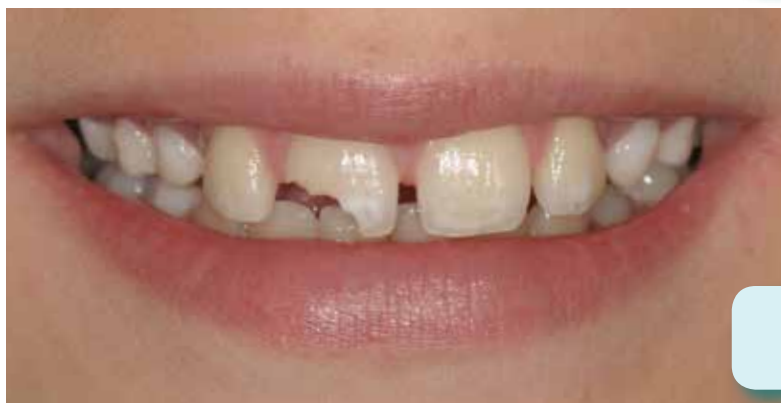

Figure 3: Preoperative 1:2 full natural smile view.

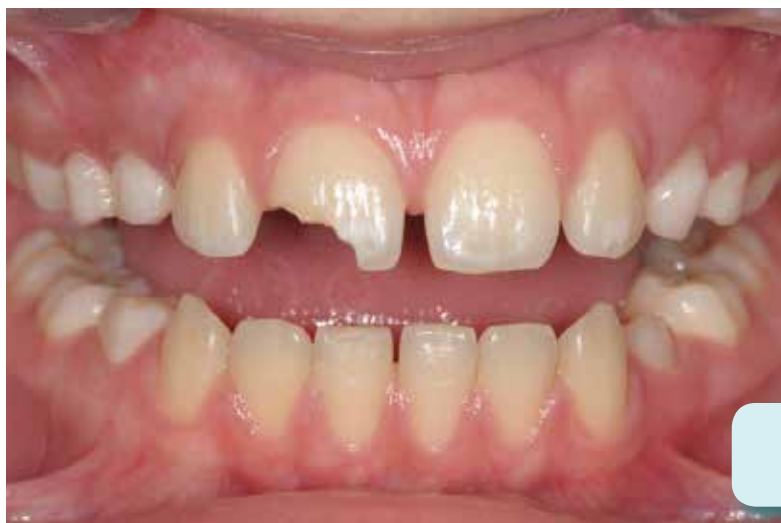

Figure 4: Preoperative 1:2 retracted frontal view.

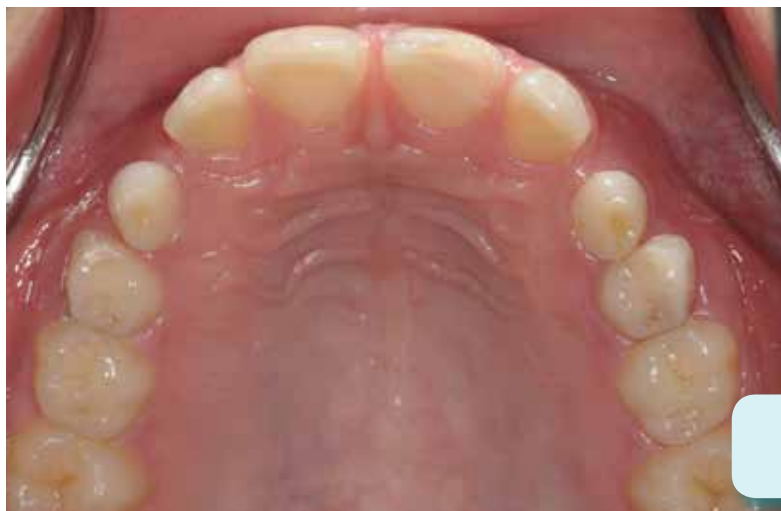

Figure 5: Preoperative 1:2 occlusal view.

4

COLOR AND TEXTURE MAPPING. Color and texture mapping were used to guide the layering of composite to achieve a polychromatic result. A topical anesthetic was applied in the buccal fold apical to #8, and the patient was anesthetized with one carpule of Septanest (Septodont; Lancaster, PA) with adrenaline 1/100,000.

5

SHADE DETERMINATION. A shade determination was done before the teeth became dehydrated and changed value during treatment. A spectrophotometer (Shadepilot, DeguDent; Hanau, Germany) reading was made on both #8 and #9 to help determine the appropriate shade of the final composite resin. The body shade was A-3 (VITA, Vident; Brea, CA). The following materials and shades were selected:

- flowable composite G-aenial Flo AO3 (GC America; Alsip, IL), as a cavity liner
- microhybrid composite G-aenial Anterior A03 for artificial dentin (AD), to provide opacity, hue, and chroma
- microhybrid composite G-aenial Anterior A2 for artificial chromatic enamel (ACE), to provide hue, chroma, and value
- Renamel Creative Color Opaquer White (Cosmedent; Chicago, IL), to reproduce whitish, opaque enamel hypoplasia effects
- Renamel Microfill Incisal Medium for artificial achromatic enamel (AAE), to create effects ranging from translucency to milky-whiteness and for polishing ease and longevity when exposed to varying degrees of pH levels (i.e., low pH, high acidity, and brushing)¹
- Adhesive Prime&Bond NT (Dentsply DeTrey GmbH; Konstanz, Germany).

6

COLOR MOCK-UP. A color mock-up was completed in the patient's mouth to verify the composite "recipe" that would mimic the colors and texture of the adjacent intact central tooth. During this process, the lingual shelf, the dentin, characteristics of white spots, and chromatic and achromatic enamels were applied to envision a highly esthetic final result. The mock-up allowed for thickness corrections prior to creation of the final restorations.^{2,3}

7

CLEANING. Prior to preparation, the teeth were cleaned using fluoride-free toothpaste (Zircate, Dentsply), prophyl brushes, and dental floss. Tooth #8 was disinfected with chlorhexidine.

8

INITIAL PREPARATION. Preparation began with a round-end diamond bur (6856-016, Brasseler USA; Savannah, GA) with a deep and long bevel extended 2 mm around the entire facial and lingual margins. This greatly increases the surface area of enamel available for bonding. When giving the preparation its final inspection, using an extra-fine diamond bur (7803, Shofu Dental; San Marcos, CA), any unstable or overhanging enamel structures were removed, as they have a negative effect on the adhesive bond of the restoration. Weak enamel structures left untrimmed at the margins lead to the so-called “prism effect” once composite is applied.⁴

9

PREPPING FOR ADHESION. The rubber dam (SigmaDam, Sigma Dental Systems GmbH; Flensburg, Germany) was applied from tooth #3 to #14. The prepared tooth #8 was sandblasted with 50 μ aluminum oxide (MicroEtcher II A, Danville Materials; San Ramon, CA) to clean the preparation and enhance adhesion.

10

ADHESION. Acid-etching with 38% phosphoric acid (Etch-Rite etching gel, Pulpdent; Watertown, MA) was performed over enamel for 30 seconds and dentin for 15 seconds to remove the smear layer, which forms after dentin preparation, and to open collagen fibers. After rinsing with water for 30 seconds, adequate humidity control is important since the total dehydration of dentin is contraindicated.⁵ When using phosphoric acid as an etchant, a wet bonding technique is necessary to keep the collagen meshwork open for resin monomer penetration. Adhesive (Prime&Bond NT) was applied, air-thinned, and light-cured for 20 seconds.

11

COMPOSITE PLACEMENT. Flowable composite was injected into the floor of the cavity ensuring there were no bubbles, and polymerized for 20 seconds using a light-emitting diode (LED) curing unit (Bluephase 20i; Ivoclar Vivadent; Amherst, NY). Applying flowable composite as a liner improves contact with the preparation walls, reducing bubbles or gaps between the adhesive layer and the composite resin.⁶ Also, the flowable composite liner reduces polymerization shrinkage stress and can act as a sort of “shock absorber.”⁷

12

CURING. Then, in three subsequent layers, AD composite (shade A03) of higher chroma than the intended enamel chroma was applied and sculpted to conform to the histological boundaries of the natural dentin and light-cured for 20 seconds each. To maximize curing effectiveness, curing light guides should be maintained in close proximity to the surface of the light-activated restorative material.⁸



“Dr. Ivance did an excellent job handling the composite resin and blending the restoration into the natural tooth structure. The color selection was well done. The milky-white incisal halo and incisal translucency mimicked the contralateral tooth.”

— James H. Peyton, DDS, FAACD

13

LAYERING. This was followed by applying a layer of ACE (shade A2) on the palatal aspect of the tooth. The palatal enamel wall was modeled freehand and light-cured for 20 seconds. This was followed by applying a layer of ACE (shade A2) on the palatal aspect of the tooth. The palatal enamel wall was modeled freehand and light-cured for 20 seconds. Then material of ACE (shade A2) was used over the labial surface of the composite.

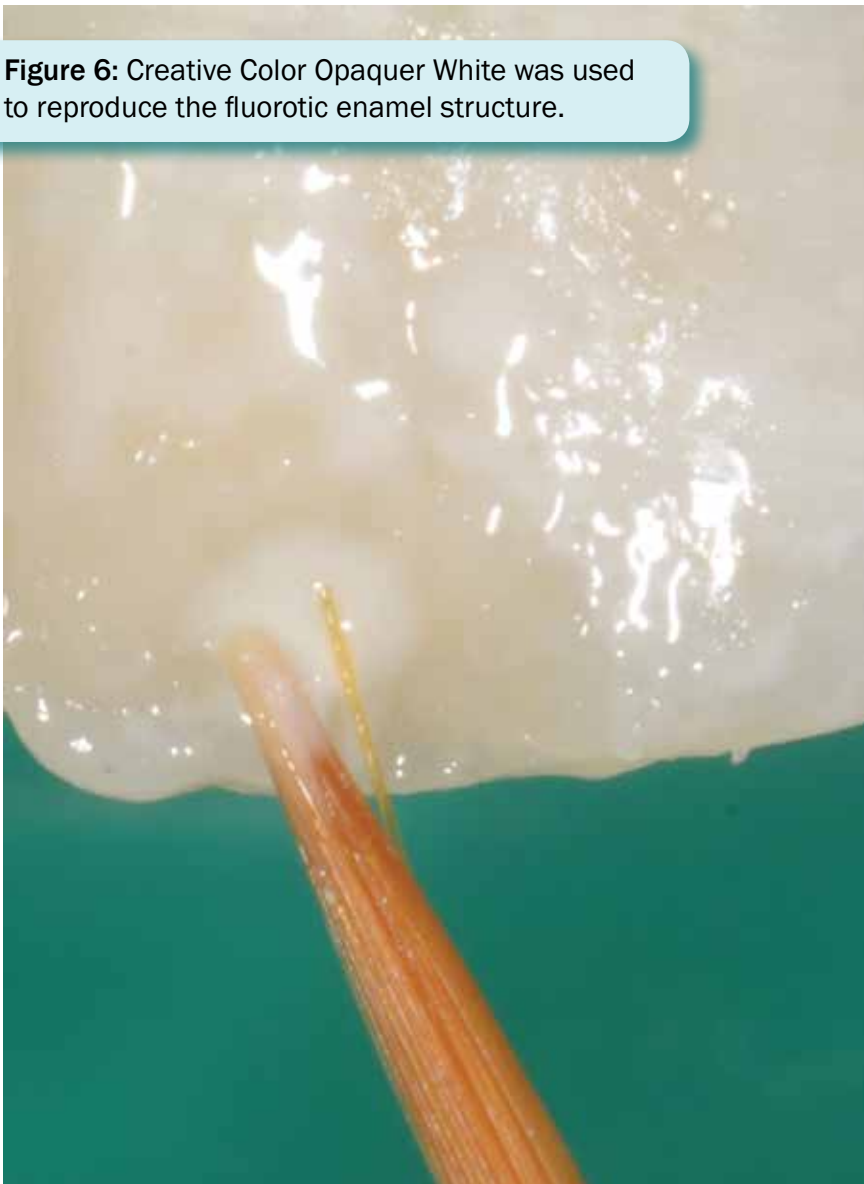14

SHAPING. This layer was smoothed and shaped with an artist's brush (#3, Cosmedent) to provide an even surface and minimize the incorporation of any air pockets. The IPCT carver (Cosmedent) was used to make a random bevel and groove for the subsequent incisal composite, and the layer was light-cured for 10 seconds.

15

CHARACTERIZING. An artist's brush (#1, Cosmedent) was used to apply patches and bands of Creative Color Opaquer White to reproduce the fluorotic enamel structure (Fig 6), as seen on tooth #9. The layer was light-cured for 20 seconds.

Figure 6: Creative Color Opaquer White was used to reproduce the fluorotic enamel structure.



“The white opaque effect was just slightly overdone, but it was very close (and it is not such an easy thing to accomplish).”

— James H. Peyton, DDS, FAACD

16

FINAL FACIAL LAYERING. A final layer of AAE composite (Incisal Medium) was applied to cover the entire facial aspect. This achromatic enamel has the ability to diffuse the light to some extent, while permitting the colors of the underlying layers to selectively show through.² The layer was cured for 20 seconds.

17

FINAL INTERPROXIMAL LAYERING. The intact cervical hard tissues of #7 and #8 allowed a transparent strip (KerrHawe; Bioggio, Switzerland) to be wedged in (Luciwedge Soft, KerrHawe), adapted, and correctly shaped. Then a thin layer of AAE composite (Incisal Medium) was applied to the facial and palatal surfaces. To achieve uniform composite transition from the facial to palatal surfaces and contour proximal surfaces in convex form, the matrix was slightly pulled to the palatal, then pressed from both sides (controlling avoidable composite overhangs on the palatal surface), and light-cured for 20 seconds. The final layer wedge, strip, and rubber dam were removed.

18

FINISHING. A composite polishing disc (Sof-Lex extra/coarse, 3M ESPE; St. Paul, MN) and flame-shaped fine and extra-fine diamonds (8859-010, 859EF-010, Brasseler) were used to remove excess material, recontour, and establish outline form. The flameshaped burs were worked along the axis of the tooth, from mesial to distal side, producing a perikymatous surface structure. The contouring was guided by comparison with the three planes of the contralateral tooth. Excess material on the palatal side was removed using a football-shaped diamond bur (6368-023, Brasseler). Symmetry of the central incisors was verified using a digital caliper (Dentagauge, Erskine Dental; Marina Del Ray, CA).

POLISHING. The proximal surface was polished using a finishing diamond strip (NTI-Kahla GmbH; Kahla, Germany). Facial and palatal surfaces were modeled with ultra-fine diamonds (LT2, 7406, Shofu). Static and dynamic occlusion was optimized using articulating film (TrollFoil, Trollhätteplast AB; Trollhättan, Sweden). All surfaces were polished using polishing points (Enhance, Dentsply) and FlexiDiscs (Cosmedent). Before the final polishing, the restoration was covered with a layer of “air-block” water-soluble glycerin (Glycerigel, Ivoclar Vivadent). Final polymerization was carried out with 20-second cycles on the palatal and facial surfaces to obtain the maximum monomer conversion in the uppermost layer of composite material, normally inhibited by oxygen.⁹ A FlexiBuff disc with Enamelize paste (both Cosmedent) was used to obtain the final gloss (Fig 7).

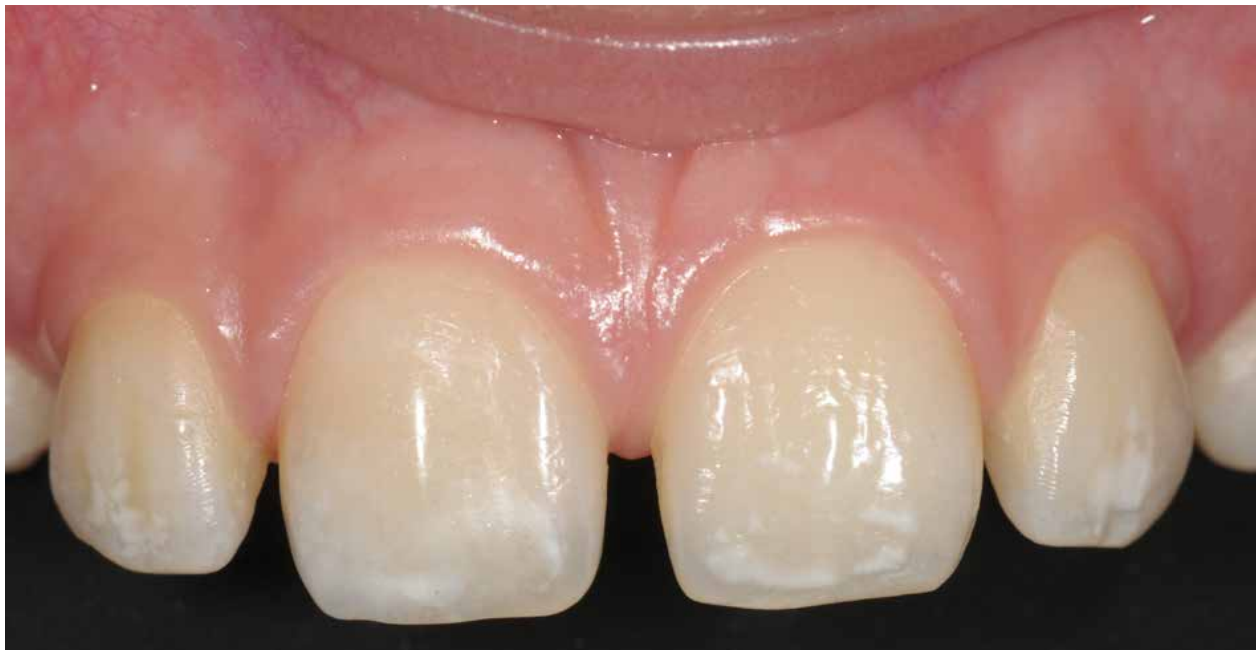

Figure 7: In the “after” 1:1 frontal view, the translucency, halo, and whitish, opaque enamel hypoplasia effects create a lifelike mirroring of the adjacent central incisor.

20

FINAL CHECK. The patient was given home care instructions and scheduled to return three days later for a final check of function and esthetics, and to complete photographic and radiographic documentation (Fig 8). He was invited for posttreatment photography six months later (Figs 9a-9c).

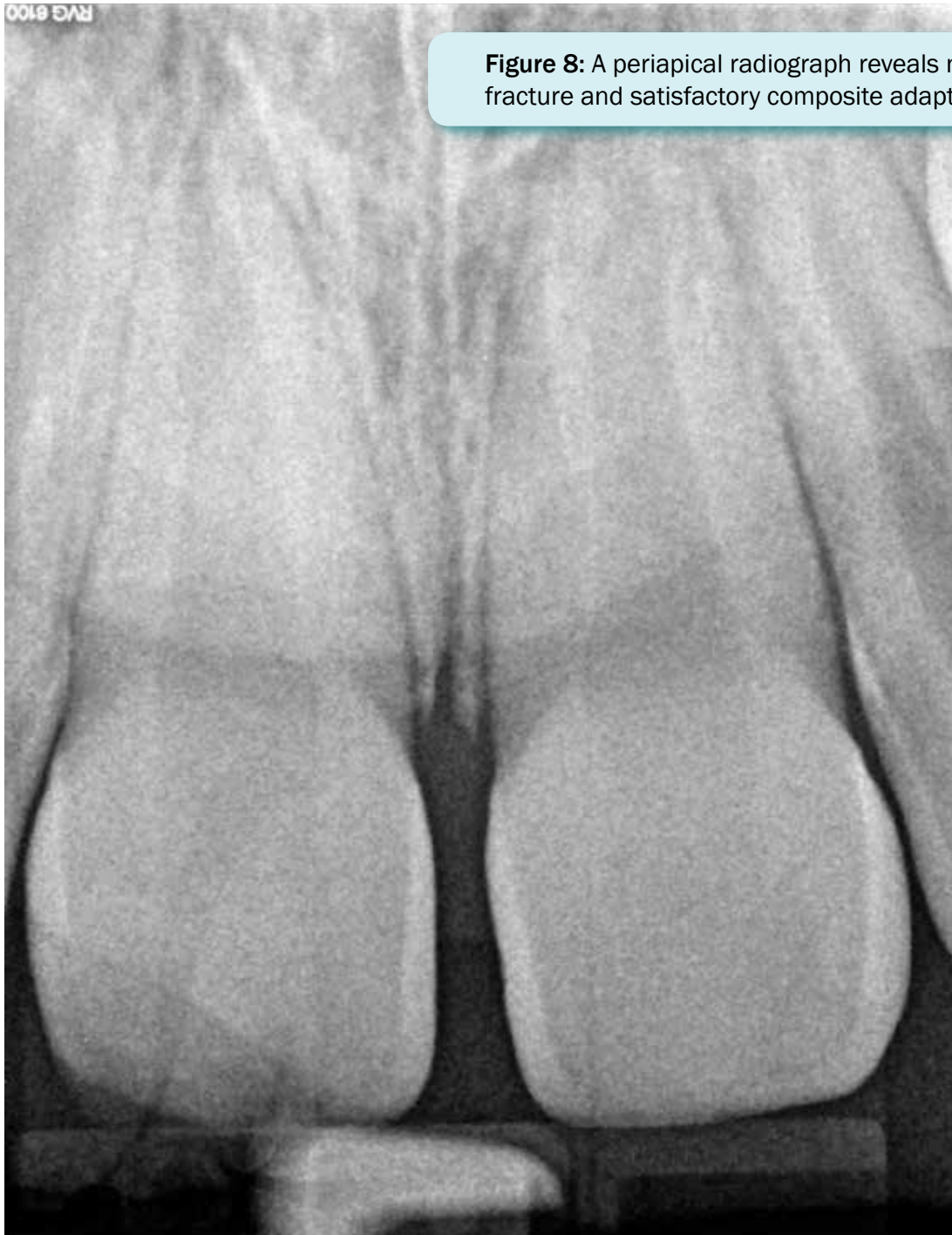

Figure 8: A periapical radiograph reveals no root fracture and satisfactory composite adaptation.

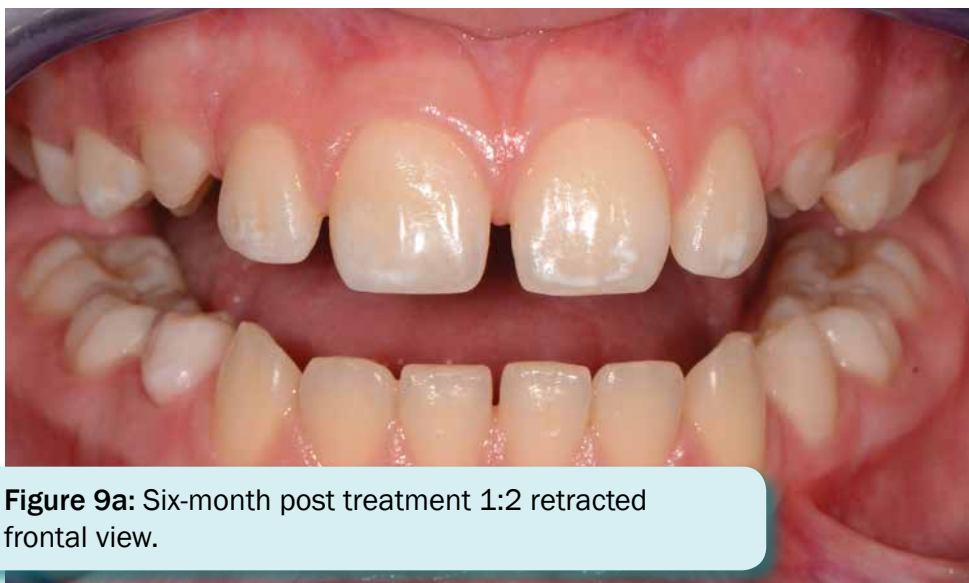

Figure 9a: Six-month post treatment 1:2 retracted frontal view.

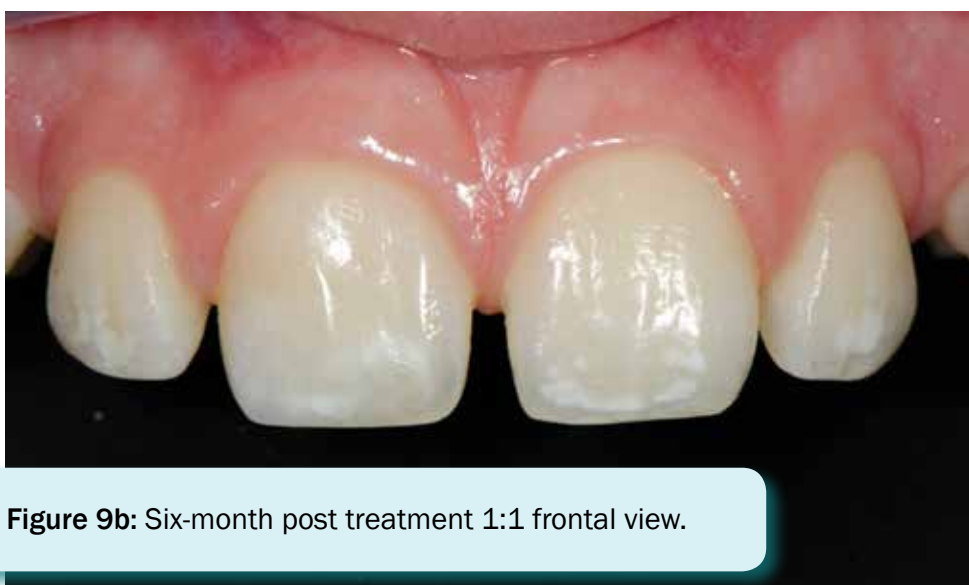

Figure 9b: Six-month post treatment 1:1 frontal view.

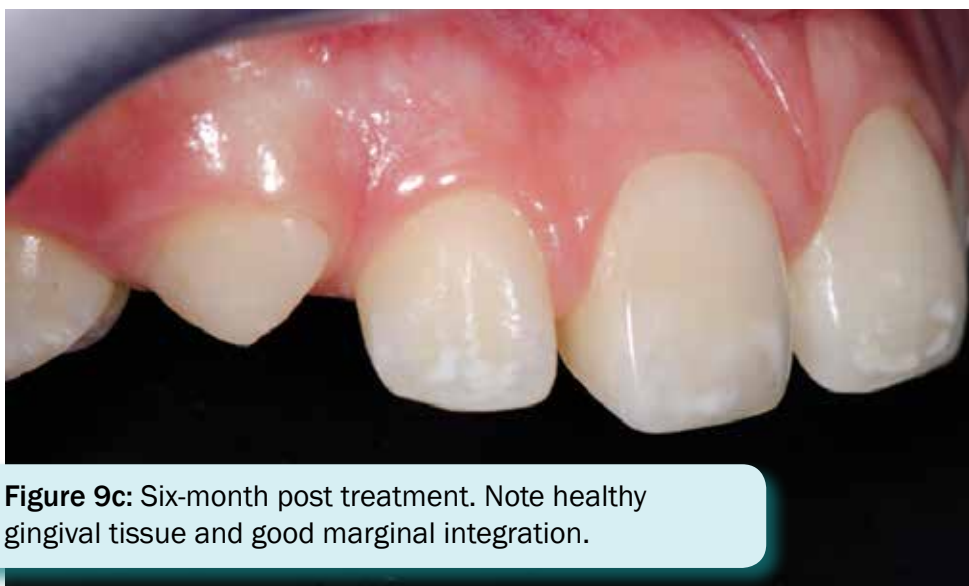

Figure 9c: Six-month post treatment. Note healthy gingival tissue and good marginal integration.

CONCLUSION

The patient and his mother were extremely happy to have avoided a more invasive crown preparation and could not believe that the restored part of the fractured tooth was virtually undetectable from the surrounding natural dentition (Fig 10).




Figure 10 : Full-face smile after, 1:10. The patient was very happy to smile confidently again.



“ This Class IV fracture case was passed by all of the examiners. However, some of their deductions were as follows:

- Criterion #61: Visible margins on the restoration.
- Criterion #44: Surface finish and polish did not mimic that of the contralateral tooth.
- Criterion #86: Tooth #8 slightly longer than tooth #9.

This case demonstrated clinical excellence and deserved to pass. However, the restoration was not perfect (few cases, if any, ever achieve perfection). A good “litmus test” for the Class IV fracture case is “Can you see the restoration?” If you have to look closely to see where the restoration is, then the case should pass. Dr. Ivance’s case passed the “litmus test” for this Accreditation case type.”

— James H. Peyton, DDS, FAACD

REFERENCES

1. Fahl N Jr. A polychromatic composite layering approach for solving a complex Class IV/direct veneer-diastema combination: part I. *Pract Proced Aesthet Dent*. 2006 Nov-Dec;18(10):641-5.
2. Fahl N Jr. Coronal reconstruction of a severely compromised central incisor with composite resins: a case report. *J Cosmetic Dent*. 2010 Spring;26(1):92-113.
3. Fahl N Jr. A solution for everyday direct restorative challenges—part 1. *J Cosmetic Dent*. 2010 Fall;26(3):56-68.
4. Hugo B. *Esthetics with resin composite: basics and techniques*. 1st ed. Berlin: Quintessence Pub.; 2008.
5. Pereira GDS, Paulillo LA, De Goes MF, Dias CT. How wet should dentin be? Comparison of methods to remove excess water during moist bonding. *J Adhes Dent*. 2001 Fall;3(3):257-64.
6. Lopes GC, Vieira LC, Araujo E. Direct composite resin restorations: a review of some clinical procedures to achieve predictable results in posterior teeth. *J Esthet Restor Dent*. 2004;16(1):19-31.
7. Cunha LG, Alonso RCB, Sobrinho LC, Sinhareti MA. Effect of resin liners and photoactivation methods on the shrinkage stress of a resin composite. *J Esthet Restor Dent*. 2006;18(1):29-36.
8. Vandewalle KS, Roberts HW, Andrus JL, Dunn WJ. Effect of light dispersion of LED curing lights on resin composite polymerization. *J Esthet Restor Dent*. 2005;17(4):244-54.
9. Gauthier MA, Stangel I, Ellis TH, Zhu XX. Oxygen inhibition in dental resins. *J Dent Res*. 2005 Aug;84(8):725-9.



Dr. Ivance is in private practice at the Aesthetic Dentistry Center VivaDens, in Vilnius, Lithuania. She also teaches direct adhesive esthetic dentistry, digital dental photography, and innovative management of the dental office.

Disclosure: The author did not report any disclosures.



Dr. Peyton is an AACD Accredited Fellow and has been an AACD Accreditation Examiner since 2000. A part-time instructor at the UCLA School of Dentistry, he practices in Bakersfield, California.

Disclosure: The author did not report any disclosures.

AACD is recognized as the most authoritative source of information on comprehensive cosmetic dentistry. Whether you pursue the highly-acclaimed Accreditation path or simply learn from case studies published in the peer-reviewed member-only publication, AACD's *Journal of Cosmetic Dentistry*, and presented at the professional conferences, membership will make a valuable and rewarding difference in your practice.

AACD membership helps you deliver what your current and prospective patients are asking for: accurate treatment planning and application of the latest and most effective cosmetic treatments. We invite you to enroll today so that you have full access and privileges.

While AACD membership differentiates your practice from others to prospective patients, the Academy's Find-a-Dentist online directory, member profile pages, and consumer awareness campaigns help new patients easily find you.

AACD membership will help you stay competitive and prosperous in today's ever-changing world of cosmetic dentistry.

Join today. Visit www.aacd.com/join